



# INTERNATIONAL JOURNAL OF ADVANCE RESEARCH, IDEAS AND INNOVATIONS IN TECHNOLOGY

ISSN: 2454-132X

Impact Factor: 6.078

(Volume 7, Issue 2 - V7I2-1343)

Available online at: <https://www.ijariit.com>

## Management of Haemangioma with Ksharasutra- A case study

Dr. Prerana Santosh Bandekar

[prerana5218@gmail.com](mailto:prerana5218@gmail.com)

Dr. J. J. Magdum Ayurvedic Medical College, Jaysingpur, Maharashtra

### ABSTRACT

A Haemangioma is developmental malformation of blood vessels and not a typical tumor. So it is considered to be an example of 'Hemartoma'. Such theory can be explained by the facts that 1) Haemangioma is often present since birth and 2) it never turns malignant. In Ayurveda Haemangioma can be compared with raktaja granthi. The diagnosis is based on clinical examination and usually straight forward by visual inspection. The treatment of Haemangioma has to be done with endurance and careful selection of procedure according to the type and site of the disease; otherwise, it may lead to cosmetic derangement or recurrence of the ailment. Indications for treatment include pain, interference with function, cosmetic embarrassment. Regarding the management of this disease, different types of treatment procedures are explained in contemporary science. In Ayurveda also, various treatment principles explained like administration of drugs internally, external application of drugs and parasurgical procedures [i.e. Raktamokshana (blood letting), Ksharakarma (chemical cauterization), Ksharasutra (medicated thread ligation) and Agnikarma (thermal cauterization)]. These indigenous treatment methods are minimal invasive procedures which do not cause the scar formation, no recurrence and found to be more beneficial in the treatment of Haemangioma. This case study will reveal the management of haemangioma through ksharasutra along with internal medications. A female patient of age 24 year complaints of small swelling on left breast. Patient was the diagnosed case of haemangioma. After required investigations and local examination of swelling, patient was planned and treated (Ksharasutra, Jatyadi taila) Ayurvedic formulatins as described in texts of Ayurveda.

**Keywords-** Heamangioma, Ksharasutra, Jatyadi Taila, Shodhana, Ropana, Raktaja Granthi.

### 1. INTRODUCTION

Vitiated Vata etc. and also medas pierced with kapha. Having affected muscle and blood produce 'vru-tonnatam' round protruded and 'Vigrathitam tu shopham' knotty swelling. This is known as granthi. Granthi is categorized to be of 5 kinds by acharya sushruta and 9 by acharya vagbhata. Raktaja granthi told by Acharya Vagbhata and Acharya Sharangdhara Raktaja Granthi present with burning over the swelling. The swelling or the region surrounding it will be yellow or red in color. The swelling suppurates quickly and easily and exudes a warm blood when pricked. There will be loss of tactile sensation. This is believed to be caused by an infestation of parasitic worms. It is 'sadhya vyadhi'.

### 2. CASE STUDY

**Chief Complains:** Patient complains of Painless Small Swelling over left breast.

**Associated Complains:** Patient complains of Itching around the swelling.


**History of Present illness:** Patient was apparently healthy 15 days back, she experiences mild itching around swelling over left breast region. She was having swelling from childhood which increased. She approached Dr. J. J. M ayurvedic college and hospital for further management.

**Past history:** Not a known case of Hypertension/ Bronchial Asthma/ Hypothyroidism/ other systemic disorders.

**Family history:** All family members said to be healthy

**Menstruation cycle:** Regular (menstruation cycle started when she was 15)

### 3. LOCAL EXAMINATION

Site of swelling- Left breast region Colour of swelling- Bright or dark red Size of Swelling- 1cm No of swelling- 1 Surface- Irregular Consistency- Soft Compressible- Yes	
--	---

**Investigations**

Hb-13gm%  
 BT-2' 35"  
 CT-8' 56"

**4. TREATMENT**

On 3/4/2021 Excision followed by ksharasutra ligation over left breast under local anaesthesia under antiseptic precaution

**Pre-operative procedures**

Consent was taken  
 Inj. xylocaine test dose sc was given  
 Inj. T.T 0.5CC IM  
 Inj. Dynapar IM

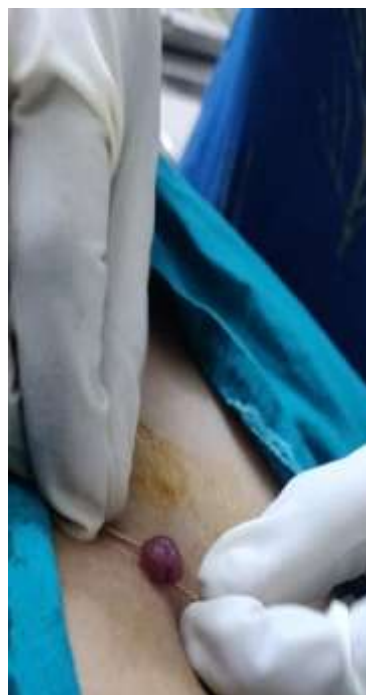**Operative Procedure**

Patient was positioned in supine position  
 Part painted and draped  
 Local anaesthesia given (inj. Lignocaine- lox 2%)  
 With the help of allis forcep the haemangioma pulled upward and ksharasutra tied in the base of hamangioma  
 Later haemangioma excised out  
 Haemostasis achieved with pressure bandage  
 Dressing done

**Post-operative procedure**

Tab. taxim o 200mg 1-0-1 AF ()  
 Tab. pan 40mg 0-1-0 BF  
 Tab. Zerodol sp 1-0-1 AF  
 Tab. Triphala guggulu 2-0-2 AF  
 Tab. gandhaka rasayana 1-1-1 AF  
 Jatyadi taila for daily dressing

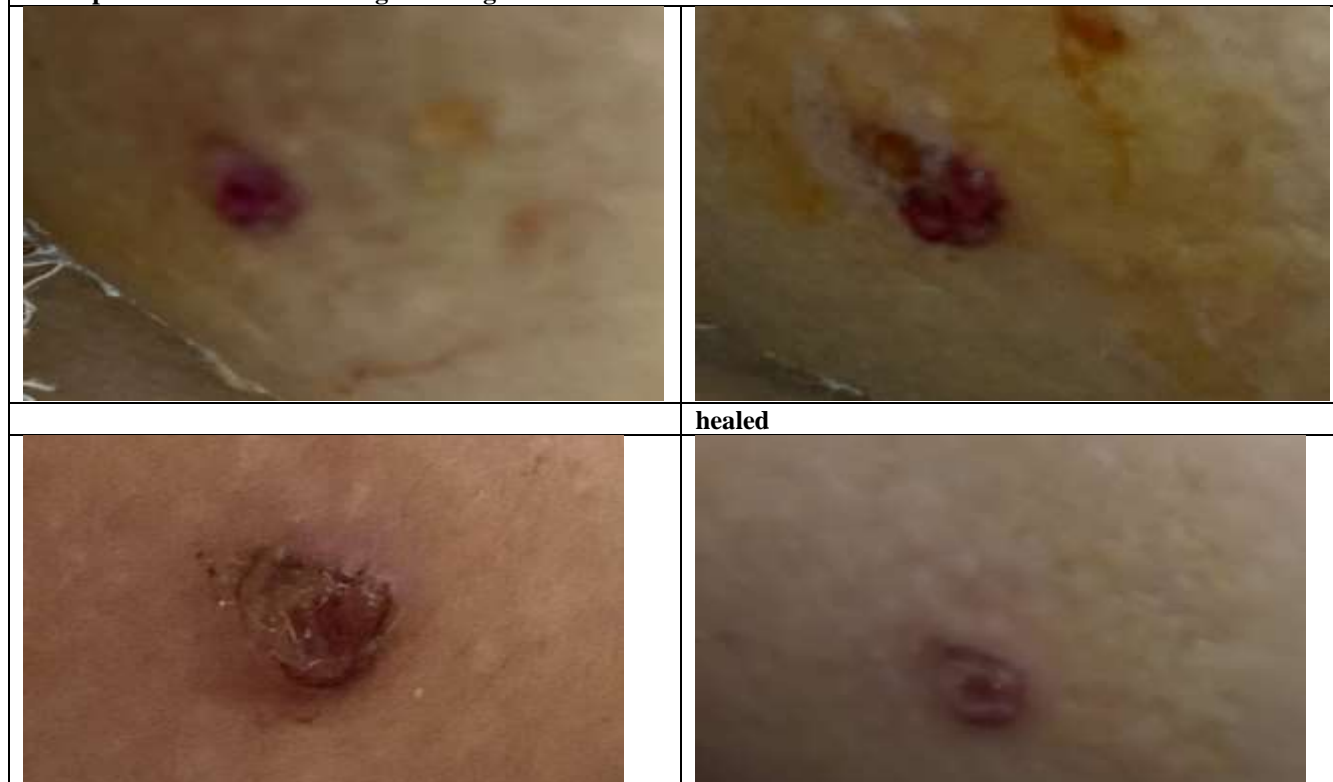3 DAYS  
 8 days



DATE	ON EXAMINATION	TREATMENT
4/4/2021	Ksharasutra in situ Mild slough Pain ++ No pus discharge No bleeding	Tab. taxim o 200mg 1-0-1 AF Tab. pan 40mg 0-1-0 BF Tab. Zerodol sp 1-0-1 AF Tab. Triphala guggulu 2-0-2 AF Tab. gandhaka rasayana 1-1-1 AF Jatyadi taila dressing
5/4/2021	Ksharasutra in situ Mild slough Pain + No pus discharge No bleeding	Tab. taxim o 200mg 1-0-1 AF Tab. pan 40mg 0-1-0 BF Tab. Zerodol sp 1-0-1 AF Tab. Triphala guggulu 2-0-2 AF Tab. gandhaka rasayana 1-1-1 AF Jatyadi taila dressing
6/4/2021	Ksharasutra falled itself No slough mild pain no pus discharge no bleeding	Tab. Triphala guggulu 2-0-2 AF Tab. gandhaka rasayana 1-1-1 AF Jatyadi taila dressing
7/4/2021	Mild pain No pus discharge No bleeding	Tab. Triphala guggulu 2-0-2 AF Tab. gandhaka rasayana 1-1-1 AF Jatyadi taila dressing
8/4/2021	No pain No pus discharge	Tab. Triphala guggulu 2-0-2 AF Tab. gandhaka rasayana 1-1-1 AF

	No bleeding Wound is healthy	Jatyadi taila dressing
9/4/10	Wound healthy	Tab. Triphala guggulu 2-0-2 AF Tab. gandhaka rasayana 1-1-1 AF Jatyadi taila dressing

Some picture were taken during dressing



**Apamarga Ksharasutra Preparation**

**Material used in preparation of Apamarga Ksharasutra**

- Barbour surgical linen thread no:20
- Apamarga kshara
- Snuhi ksheera
- Haridra choorna
- Ksharasutra cabinet



- The surgical linen thread was autoclaved and mounted on the hangers
- A piece of folded gauze was taken, dipped in Snuhi ksheera and the thread was smeared with Snuhi ksheera
- Second smearing was done only when the previous coating was dried
- The thread was smeared with Snuhi ksheera for 11 times in this manner
- The threads were placed in the ksharasutra cabinet for drying after each coating
- The temperature inside the chamber was maintained 40 degree
- After completing the first 11 coating of snuhi ksheera,next coating of the thread done by snuhi ksheera and apamarga kshara. Snuhi ksheera was first coated over a thread and later apamarga kshara was coated on it immediately(i.e when the thread is still wet) so that its stick to the thread properly
- The thread was coated with snuhi ksheera and apamarga kshar for 7 time in this way only when the previous coating got completely dried
- The last 3 coatings were given with snuhi ksheera and haridra choorna.this was done in same way as that of previous one
- While applying each coat, care should be taken that the drugs spreads evenly on all the sides of the thread
- Total number of coatings should be 21 times
- Later the dried sutras were sterilized in the cabinet and then preserved in sterile glass tubes

**5. DISCUSSION**

- The treatment of Heamangioma with above ayurvedic drugs is found satisfactory
- In this case we have used both external and internal medications

- Ksharasutra in haemangioma has shown good result
  - The ingredients of Apamarga kshara sutra are Snuhi ksheera, Apamarga kshara and Haridra powder.
  - Snuhi ksheera having shodhana as well as ropana properties along with katu,tikta ras and ushna virya thus improve process of healing its cures infection and inflammation.
  - Apamarga kshara has properties of kshara that is chhedana, bhedana, lekhana and tridoshaghna. Chitraka kshara on ksharasutra cauterize the soft tissue
  - Haridra powder has the properties like Rakta shodhana, Twak doshahara, shothahara, vatahara, vishagna and it is useful
  - The action of turmeric powder has the effect of bactericidal action with healing properties
  - Ksharasutra has got validation in the modern books also and is successful proven method for treating skin surface level and anorectal disorders
- Triphala guggulu and gandhaka rasayana acts as vrana shodhana and ropana which helped in faster healing

## **6. CONCLUSION**

- Haemangioma is an important commonest disease it is developemental malformation of blood vessels and not a typical tumor
- Ksharasutra therapy very cost effective treatment with no complications
- Ksharasutra is very effective with minimum invasive surgical modality for management of raktaja granthi.

## **7. REFERENCES**

- [1] Somen das , A concise Textbook of surgery, 3<sup>rd</sup> edition 2011, reprinted April 2004, chapter 10 pg no 94
- [2] P V Sharma.Sushruta samhita Sushrutha sutra sthana; volume 1<sup>st</sup>,reprint. Ch.11 ver.3, varansi: choukhambha Sanskrit samsthan; 2018; p-113
- [3] P V Sharama. Sushruta samhita Sushrutha chikitsa sthana; volume 2<sup>nd</sup> ,reprint. Ch.17 ver.29,30,31,32,33, varansi: choukhambha Sanskrit samsthan; 2018; p-430
- [4] Sharangdhar Samhita by Late pt. Khooba chand sharma, lukhnow: tej kumar book depot Pvt Ltd, Reprint, Khanda 1, 2014; 7/67: 175-177
- [5] Ashtanga Hridaya of Srimada Vagbhata by Dr. Bramhananda Tripathi, Edited by Nirmala hindi commentary, Delhi: Choukhambha Sanskrit pratishthan, Reprint, Uttar sthana, 2015; 29/ 2-13: 1099
- [6] P V Sharma. Sushruta samhita Sushrutha chikitsa sthana; volume 2<sup>nd</sup> ,reprint. Ch.1 ver.9, varansi: choukhambha Sanskrit samsthan; 2018; p-250