



INTERNATIONAL JOURNAL OF ADVANCE RESEARCH, IDEAS AND INNOVATIONS IN TECHNOLOGY

ISSN: 2454-132X

Impact factor: 4.295

(Volume3, Issue3)

Available online at www.ijariit.com

Traumatic Fibroma of the Upper Lip: Case Report of an Uncommon Presentation

Dr. Monica

K. D Dental College and Hospital, Uttar Pradesh

monica.alive@gmail.com

Abstract: *Local reactive focal overgrowths are frequently found in the oral cavities. Different types of localized reactive lesions may occur on the gingiva, including focal fibrous hyperplasia, pyogenic granuloma, peripheral giant cell granuloma and peripheral ossifying fibroma (POF). The inflammatory hyperplastic lesion may be defined as “an increase in the size of an organ or tissue due to an increase in the number of constituent cells, as a local response of tissue to injury. Irritation fibroma clinically resembles as pyogenic granuloma, peripheral giant cell granuloma or odontogenic tumors, so radiographic and histopathological examination is essential for accurate diagnosis.*

Keywords: *Traumatic Fibroma, Pyogenic Granuloma.*

INTRODUCTION

Local reactive focal overgrowths are frequently found in the oral cavities. Different types of localized reactive lesions may occur on the gingiva, including focal fibrous hyperplasia, pyogenic granuloma, peripheral giant cell granuloma and peripheral ossifying fibroma (POF). The inflammatory hyperplastic lesion may be defined as “an increase in the size of an organ or tissue due to an increase in the number of constituent cells, as a local response of tissue to injury. The traumatic irritants include calculi, overhanging margins, restorations, foreign bodies, chronic biting, margins of caries and sharp spicules of bones and overextended borders of appliances.¹ Fibrous hyperplasia (traumatic or irritation fibroma) is the healed end product of the inflammatory hyperplastic lesion. This paper reports a case of Irritation fibroma in a 50 years old female in relation to the upper lip.

CASE REPORT

A 50 years old female patient reported to the outpatient department with a chief complaint of a mass on the lip for last 6 to 7 months. The medical history was not contributory. The lesion started as a small painless nodule which gradually increased in size with no history of bleeding, paresthesia and pain. Intra-oral clinical examination revealed a multilobular exophytic growth in relation to upper lip, measuring approximately 7 mm x 5 mm in diameter. The overlying mucosa was bluish in color, ulcerated and showed no vascular markings. The mass was firm in consistency, sessile, non-tender and no bruit or pulse was felt. On the basis of history and clinical findings, a provisional diagnosis of irritation fibroma was given.

The investigations included complete hemogram and excisional biopsy of the lesion. Routine hematological investigation values were also found to be within normal limits. The excisional biopsy was performed under local anesthesia and H&E stained section revealed para keratinized stratified squamous epithelium with elongated rete ridges. Irregular multiple foci of homogenous calcified areas were evident within the connective tissue. Thus, a final diagnosis of Irritation fibroma was given.

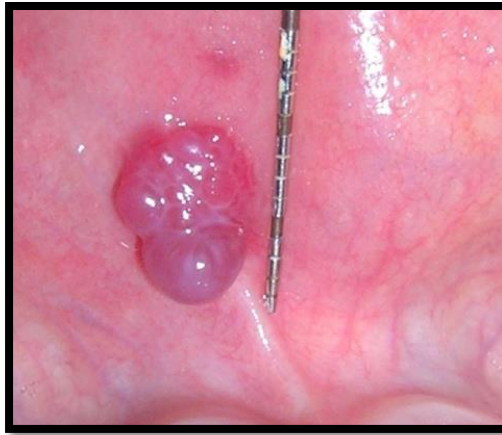


Fig 1: vertical dimension of lesion

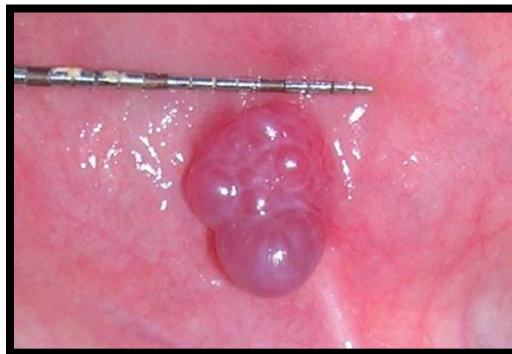

Fig 2: horizontal dimension of lesion

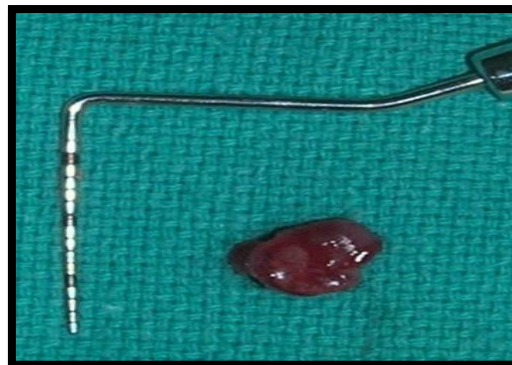

Fig 3: excised lesion

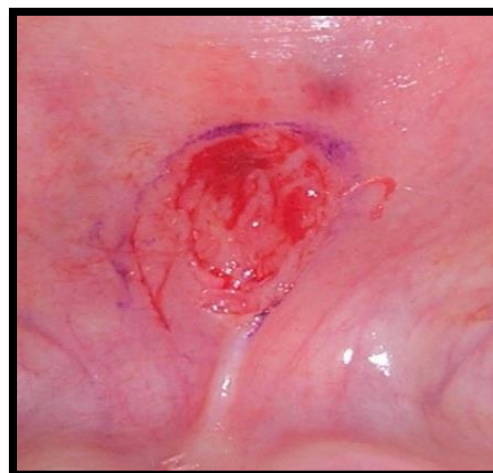


Fig 4: site after excision

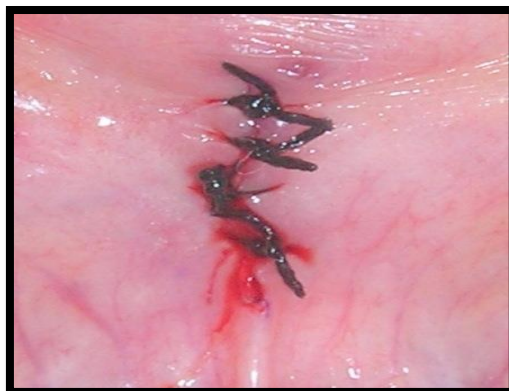

Fig 5: interrupted sutures placed

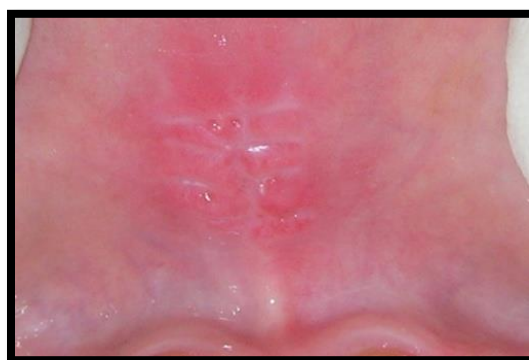

Fig 6: completely healed site after 15 days

DISCUSSION

Unhealthy habits, when repeated excessively become harmful, contributing to orofacial muscular imbalance associated with alterations in bone growth, dental malposition, and dentofacial abnormalities. Biting, licking, or sucking of lips and cheeks is frequently accompanied by chapping, dryness, erosion, irritation of one of both lips and/or vermillion borders.²

Fibroma is the most common benign soft tissue tumor in the oral cavity. Most fibroma represents reactive focal fibrous hyperplasia due to trauma or local irritation. An interesting point to be noted is that the fibroma is a neoplasm of connective tissue origin and microscopically similar to inflammatory hyperplasia. Hyperplasia is a self-limiting process unlike neoplasia and hyperplastic cells sometimes show regression after removal of the stimulus.³

Treatment of irritation fibroma consists of elimination of etiological factors, scaling of adjacent teeth and total aggressive surgical excision along with involved periodontal ligament and periosteum to minimize the possibility of recurrence. Any identifiable irritant such as an ill-fitting dental appliance and rough restoration should be removed.⁴

CONCLUSION

Irritation fibroma clinically resembles as pyogenic granuloma, peripheral giant cell granuloma or odontogenic tumors, so radiographic and histopathological examination is essential for accurate diagnosis.⁵

REFERENCES

1. Al-Rawi NH. Localized reactive hyperplastic lesions of the gingiva: a clinicopathological study of 636 lesions in Iraq. *Internet Journal of Dental Science*. 2009; 7(1).
2. Kolte AP, Kolte RA, Shirao TS. Focal fibrous overgrowths: A case series and review of the literature. *Contemporary clinical dentistry*. 2010; 1(4):271.
3. Mathur LK, Bhalodi AP, Manohar B, Bhatia A, Rai N, Mathur A. Focal fibrous hyperplasia: a case report. *International Journal of Dental Clinics*. 2010; 2(4).
4. Das U, Azher U. Peripheral ossifying fibroma. *Journal of Indian Society of Pedodontics and Preventive Dentistry*. 2009; 27(1):49.
5. Bagde H. Peripheral Cemento Ossifying Fibroma—Case Report. *Int J Dent Case Reports*. 2012; 2(5):15-8.