



INTERNATIONAL JOURNAL OF ADVANCE RESEARCH, IDEAS AND INNOVATIONS IN TECHNOLOGY

ISSN: 2454-132X

Impact factor: 4.295

(Volume3, Issue1)

Available online at: www.ijariit.com

Anatomical Variations of Nose and Para-Nasal Sinuses; CT Scan Review in South Gujarat

Dr. Abhishek S
SSG Hospital and Medical College,
Vadodara, Gujarat, India.
abhishekmandya52@gmail.com

Dr. Bhavtik Kapadia
SSG Hospital and Medical College,
Vadodara, Gujarat, India.
ssgrad02007@gmail.com

Dr. Nandakishore G. Patil
SSG Hospital and Medical College,
Vadodara, Gujarat, India.
nandakishorepatil88@gmail.com

Dr. Girbide Shubhangi
SSG Hospital and Medical College,
Vadodara, Gujarat, India.
girbideshubangi@gmail.com

Abstract -Objective: To identify frequency and characters of anatomic variations in paranasal sinuses in computed tomography scan of para-nasal sinuses.

Methods: The retrospective study was conducted at the SSG Hospital, Baroda, and comprised computed tomography scans of 75 patients who had presented between December 2016 and January 2017.

The scans were reviewed for the presence of deviated nasal septum, paradoxical middle turbinate, Haller cell, Onodi cell, and pneumatization of the middle turbinate and uncinata process.

Results: The mean age of the patients was 32 ± 13.15 years. The most frequent variant being the deviated nasal septum 32 (63%) and the middle nasal Concha 16 (22%).

Conclusion: Computed tomography is excellent means of providing anatomical information of paranasal sinuses considering the wide range of variations in the anatomy, each and every para-nasal sinus case should be planned individually and carefully to avoid dreadful complications and maximize patients' benefit.

Keywords: Anatomic variations, Para-nasal sinuses, deviated nasal septum, Concha bullosa.

I. INTRODUCTION

Computed tomography of the para-nasal sinuses is the investigation of choice for the radiological diagnosis of nasal and sinus diseases.

1 CT shows an excellent anatomical soft tissue and bony details, helps in the diagnosis, and gives detail of sinonasal anatomy.

2 knowledge of the variations in every patient is important before surgery is planned to avoid damage to surrounding vital structures like the orbit and the brain.

3 In review of literature, there is no data on anatomical variations of nose and PNS in our population. The aim of this study was to report the frequency of these variations in patients, who underwent CT scan in the SSG hospital Baroda.

NASAL SEPTUM

The nasal septum is fundamental in the development of the nose and paranasal sinuses. It is "epiphyseal platform" for the development of the facial skeleton. The three components of the adult nasal septum (septal cartilage, perpendicular plate for ethmoid lamina, and delimited by the vomer) give rise to a deviation of the septum (figure 1A & B) associated with deformities or asymmetry of the adjacent turbinates. Reported that nontraumatic septal deviation is observed in some 20% of the population.

CONCHA BULLOSA

Concha bullosa (Figure 3A) is a variation originated from pneumatization of the bone plate by extension of the ethmoid sinus cells. Such variation may be either uni- or bilateral. Varied degrees of pneumatization of the concha may be observed, possibly

causing middle meatus or infundibulum obstruction, besides being related to deviation of the nasal septum to the contralateral side. Other variation is frequently associated with septal deviation.

UNCINATE PROCESS VARIATIONS

The uncinat process projects from the ethmoid process of the inferior nasal concha and it is a superior extension of the lateral nasal wall that is anatomically relevant for draining the frontal recess. Variations such as hypertrophy, deviation and pneumatization may affect the drainage, generating abnormalities in the ostiomeatal complex and predisposing to obstruction. Pneumatization of the uncinat process (uncinat bulla) is a rare entity and this anatomic variation may result in anatomic narrowing of the infundibulum and can impair sinus ventilation.

ETHMOID CELLS VARIATIONS

Haller cells (infraorbital ethmoid cells Figure 4C) are ethmoid air cells located anteriorly to the ethmoid bulla, along the orbital floor, adjacent to the natural ostium of the maxillary sinus, which may cause mucociliary drainage obstruction, predisposing to the development of sinusitis. Agger nasi cells, which are the most anterior ethmoid cells, are located anteriorly to the upper margin of the nasolacrimal duct and anteriorly to the plane of the maxillary sinus infundibulum. The agger nasi cell can be an important factor in selected cases of frontal sinusitis. The giant agger nasi cell caused sinusitis by obstruction of the frontal sinuses' drainage pathway. The posterior ethmoid cells may invade the posterior ethmoid capsule or migrate to the medial aspect of the optic nerve. These then take the name of Onodi cells (spheno-ethmoid cells. Figure 2A) and are located between the sphenoid sinus and the floor of the anterior cranial fossa. The presence of an Onodi cell may possibly contribute to increased risk of injury to the optic nerve and mucocele of an Onodi cell causing optic neuropathy is extremely rare. The ethmoid bulla is the largest air cell of the ethmoid complex. When this air cell reaches sufficient size it can tighten or even obstruct the middle nasal meatus and the infundibulum. Therefore, it is considered as a great ethmoid bulla (Figure 4B,4D).

MAXILLARY SINUSES SEPTA

Maxillary sinus septa are thin walls of cortical bone present within the maxillary sinus, with variable number, thickness and length. Such septa may divide the sinus into two or more cavities arising from the inferior and lateral walls of the sinus. Septa originating from teeth may be classified according to their development at different phases of dental eruption.

MATERIALS AND METHODS

The study comprised 77 CTs of the nasal sinus region taken in patients of head injury and suspected of cerebrovascular accidents presented to SSG hospital Baroda

In all cases, systematic studies of the nasal sinus region were performed in coronal and in axial scans. Direct scans 3 mm in thickness were made, from the anterior walls of the frontal sinuses to the posterior wall of the sphenoid sinus. For the axial scans, which were 5 mm thick, the orbitomeatal line was taken as reference. Parallel scans were made upwards from the upper dental arch to the roof of the frontal sinuses.

In all cases, the existence of the following variants was investigated: (1) nasal septum: septal deviation, septal bony spur. (2) middle nasal concha: concha bullosa, paradoxical (false) middle concha, hypoplasia of middle concha; (3) ethmoid uncinat process: deviation of the upper edge, pneumatization; (4) ethmoid air cells: agger nasi cells, Haller cells, great ethmoid bulla, Onodi cells (5) other variants: hypoplasia of the maxillary sinus and asymmetry of both cavities of the sphenoid sinus.

II. RESULTS

Result of the 75 cases studied, 52 (69%) presented some anatomical variant and, in many, more than one variant was present in the same subject. In absolute percentage terms, the highest degree of variability was for the nasal septum (63%), followed by the middle nasal concha (22%), the ethmoidal air cells (09%), the ethmoidal uncinat process (4%) and other sites (3%).

Nasal septum

We detected 32 variants at this site. Most were nontraumatic deviations of the septum (24 cases, 75%); the numbers of left and rightward deviations were similar, with a slight predominance of the former. The rest of the variants found were septal bony spurs (12 cases, 25%;).

Middle nasal concha

The middle nasal concha is normally a bone. When it becomes pneumatized by extension of anterior ethmoid cells or, less frequently, posterior ones, it is referred to as concha bullosa. The true concha bullosa is produced following pneumatization of both portions (vertical lamina and inferior bulb) of the middle nasal concha. With this criterion, a concha bullosa (Fig. 3A) was detected in

16 of 75 cases (22%) showing any anatomical variant of the middle nasal concha. Of these, in 8 cases it appeared only on the left side, in 7 only on the right and in 1 was bilateral. In our series, there were no instances of a hypoplastic middle concha or of a secondary middle concha.

Uncinat process of the ethmoid bone (Fig.4A)

All 3 variants at this site were a deviation of its upper edge. In 2 cases, the deviation was bilateral, while it appeared only on the right side in 1 case each. No example of pneumatization was observed.

Ethmoid sinuses

Of the 07 variants observed, 3 (42%) were the so called Onodi air cells (Fig. 2A), while the 2 remaining cases (28%) showed the presence of Haller air cells (Fig. 4C). 2 cases (28%) with a great ethmoidal bulla (Fig.4B, 4D) were encountered.

Other sites

In 2 cases hypoplasia of the maxillary sinus (Fig.5A) were detected. A hypoplastic sinus shows a much thicker anterior wall than normal and the pterygoid plates posteriorly have an abnormal lateral angulation.

Additionally, the medial wall of the sinus is characteristically laterally placed and there is an inferior displacement of the orbital floor (Mancuso & Hanafee, 1982). The hypoplasia was bilateral in 1 case, and in the remainder it was found on the left side.

III. DISCUSSION

In our series the deviation of the nasal septum and the presence of a bony spur, the variants of the middle nasal concha, especially its great pneumatization (concha bullosa), and others mentioned, the most frequently observed variants. These data are in accord with those of the series studied by Scribano et al. (1993). However, Zinreich (1993) reported the concha bullosa (36%) as the most common, followed in descending order by deviation of the nasal septum (21%), a paradoxical middle concha (15%), Haller cells (10%), a prominent ethmoid bulla (9%) and, finally, deviation (3%) and pneumatization (0.4%) of the ethmoid uncinat process.

Nasal septum

According to Blaugrund (1989), nontraumatic septal deviation is observed in some 20% of the population. The proportion increased to 44% in the series studied by Earwaker (1993). That author also observed presence of a bony spur on the septum in 7.2%. In our series, we observed the frequency of septal deviation (32%) and the presence of septal spurs (16%).

Middle nasal concha

The presence of a concha bullosa has ranged between 4% and 80% in different studies; our data gave 12%. Such a wide range of incidence is due to the criteria of pneumatization adopted. With the criterion also used by us, Bolger et al. (1991) observed the variant in 15±7% of the population. However, if any degree of pneumatization is considered, the incidence increases to 34% (Zinreich et al. 1988).

Uncinate process of the ethmoidal bone

The uncinat process is a key bony structure of the lateral wall of the nasal cavity. Together with the ethmoid bulla, it limits the semilunar hiatus and the ethmoid infundibulum, where the frontal and maxillary sinuses drain. The upper edge of the uncinat process may present lateral, medial, or anterior deviation with respect to the middle nasal meatus, appearing as a second middle concha (Stammberger & Wolf, 1988). When the deviation is lateral, it can result in narrowing of the semilunar hiatus and infundibulum, jeopardising their patency. When the deviation is medial, the uncinat process makes contact with the middle nasal meatus, threatening its permeability. The exact incidence of these variants is not known. Earwaker (1993) observed a horizontal orientation of the uncinat process, unilaterally or bilaterally, in 19% of cases (ours were 4.5%). In 95% of these, the variant was associated with a great ethmoidal bulla and, in some cases, with contralateral septal deviation. In 32% of cases, that author observed a vertical orientation of the process which appeared enlarged or deformed in 2±6%.

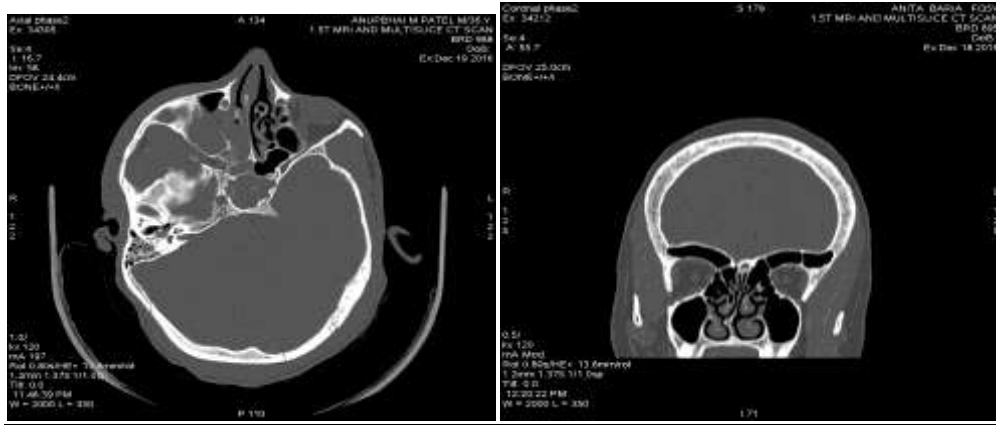
Ethmoid sinuses

The prevalence of the extramural cells, known as Onodi cells (Onodi, 1910), varies: 10% (Schaefer, 1989), 96% (Earwaker, 1993), and 98% in the series of Van Alyea (1939); our data are closer to the low end (5%). And the prevalence of agger nasi cells is (4%).

Other variants

Hypoplasia of the maxillary sinus, which in our series was present in 3% of cases, was reported in 10±4% of cases by Bolger et al. (1990). In such cases, it is important to detect variants of the ethmoidal uncinat process, as this is a significant anatomical sign post in sinus surgery to prevent inadvertent penetration of the medial wall of the orbit (Bolger et al. 1990)

Stammberger & Wolf (1988) detected the presence of anatomical variants both in patients studied for sinus problems and in those studied for other reasons. They concluded that the simple presence of variants does not mean a predisposition to sinus pathology, except when other associated factors are present.



Figures. 1A, 1B. Deviated nasal septum.

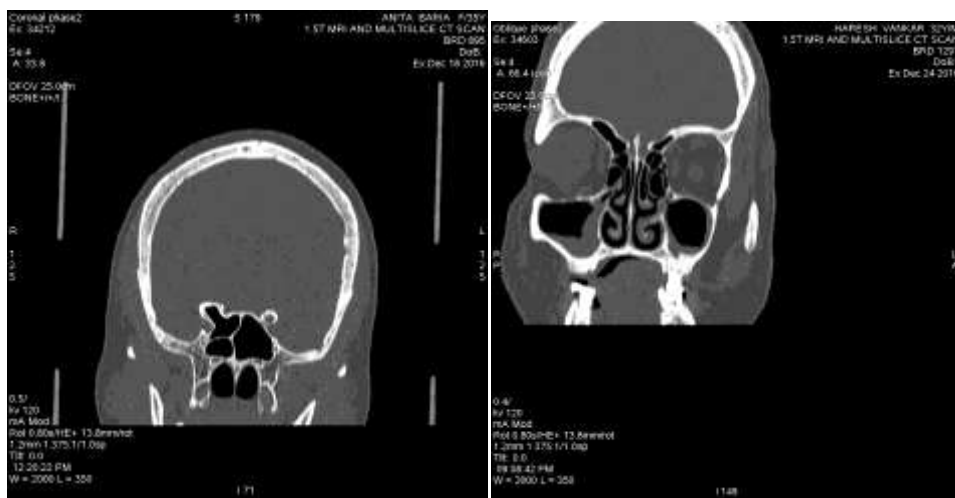
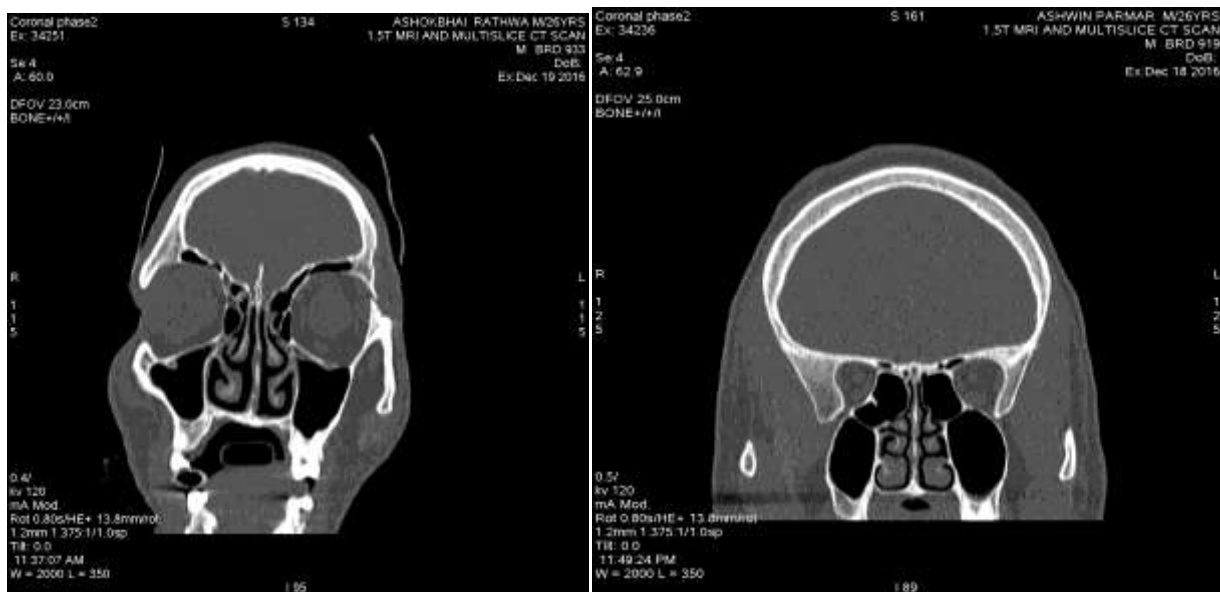

Figure: 2a.Onodi cell.

Figure: 3a, Pneumatisation of Bilateral Middle Turbinate's



Figure; 4a (laterally deviated uncinate process). 4b, 4d (ethmoidal bullae).4c Haller Cell

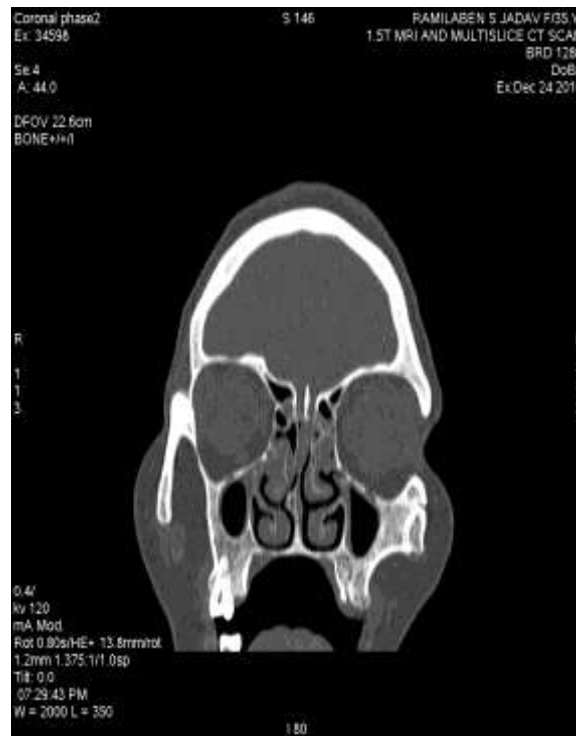
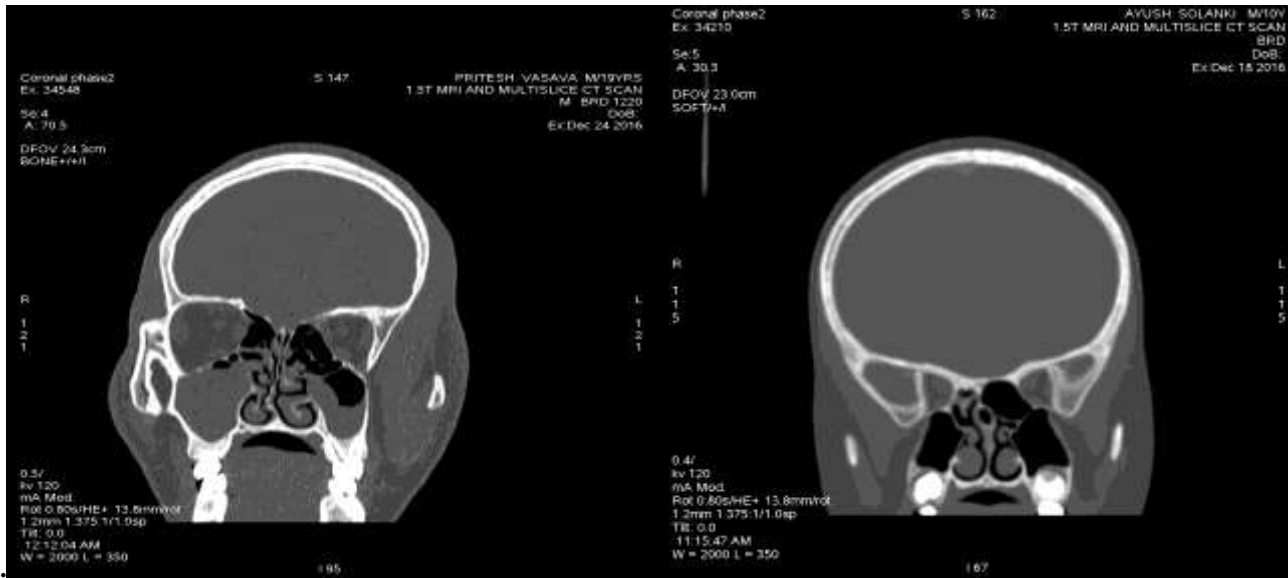


Figure: 5a. Hypoplastic maxillary sinuses.

REFERENCES

1. Paranasal sinuses in symptomatic and asymptomatic populations. *Otolaryngology for Head and Neck Surgery* 104, 480±483.
2. CHOW J, MAFEE MF (1989) Valoracio!n radiogra!@ca preoperatoria para cirug!a endosco!pica de senos paranasales. *Otolaryngology Clinics of North America* 22, 657±667.
3. EARWAKER J (1993) Anatomic variants in sinonasal CT. *Radiographics* 13, 381±415.
4. GOLDMAN JL (1987) *The Principles and Practice of Rhinology: A Text on the Diseases and Surgery of the Nose and Paranasal Sinuses*, pp. 89±95. New York: Wiley.
5. Kazkayasi M, Karadeniz Y, Arıkan OK. Anatomic variations of the sphenoid sinus on computed tomography. *Rhinology*. 2005; 43: 109-114.
6. Kayalıođlu G, Oyar O, Govsa F. Nasal cavity and paranasal sinus bony variations: a computed tomographic study. *Rhinology*. 2000; 38: 108-113.
7. Kennedy DW, Zinreich SJ. Functional endoscopic approach to inflammatory sinus disease: current perspectives and technique. *Am J Rhinol*. 1988; 2: 89-96.
8. Baradaranfar MH, Labibi M. Anatomic variations of the paranasal sinuses in patients with chronic sinusitis and their correlation with CT scan staging. *Acta Medica Iranica*. 2007; 45: 477-480.
9. Talaiepour AR, Sazgar AA, Bagheri A. Anatomic variations of the paranasal sinuses on CT scan images. *Journal of Dentistry, Tehran University of Medical Sciences*. 2005; 2: 142-146.

10. Fadda GL, Rosso S, Aversa S, Petrelli A, Ondolo C, Succo G. Multiparametric statistical correlations between paranasal sinus anatomic variations and chronic rhinosinusitis. *Acta Otorhinolaryngol Ital.* 2012; 32: 244-251.